"Auslagen mit Einlagen", Fussprobleme in der Hausarztpraxis - Die Moderne Fuss-/Sprunggelenkschirurgie

Victor Valderrabano

SWISS MEDICAL NETWORK

Der Fuss & Das Sprunggelenk

Der Fuss & Das Sprunggelenk

Der Fuss & Das Sprunggelenk

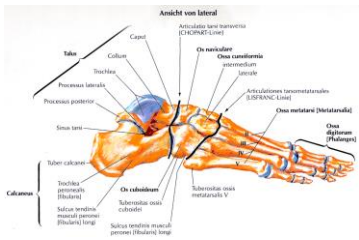

26 Knochen, > 30 Gelenken

Der Fuss & Das Sprunggelenk

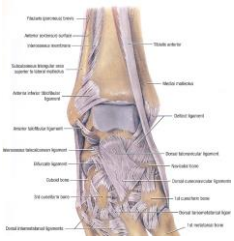

Unzählige Bänder, Muskel, Sehnen

Der Fuss & Das Sprunggelenk

Der Fuss & Das Sprunggelenk

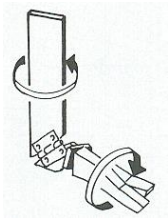

Supination/Inversion
→ Tibia-Aussenrotation

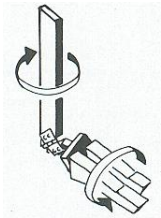

Pronation/Eversion
→ Tibia-Innenrotation

Inman, 1991

Der Fuss & Das Sprunggelenk

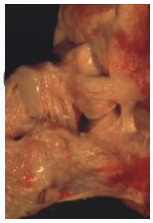

Supination/Inversion
→ Tibia-Aussenrotation

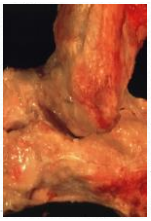

Pronation/Eversion
→ Tibia-Innenrotation

Inman, 1991

Oberes Sprunggelenk

Sprunggelenkinstabilität

Akute Sprunggelenksinstabilität

Akute Sprunggelenksinstabilität

Häufigste Sportverletzung:

- Inzidenz: USA: 23,000/d [1]
- 10% aller Notfallkonsultationen in USA[2]
- Bis 40% aller Athleten-Läsionen [3]
- Bis 53% aller Läsionen im Basketball [4,5]
- Bis 29% aller Fussball-Läsionen [4,5]

[1] Holmer et al, Foot Ankle Int, 1994; [2] Berlet et al, Foot Ankle Clin, 1999; [3] Balduini et al, Sports Med, 1987; [4] Garrick & Requa, Med Sci Sports, 1973; [5] Ekstrand & Gillquist, Med Sci Sports, 1983.

Akute Sprunggelenksinstabilität

Inversions-Trauma:
ca. 75% aller Distorsionen
laterale Bänder
OCL

Eversions-Trauma:
ca. 25% aller Distorsionen
medial Bänder
Syndesmose-Läsion
OCL

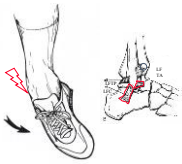

Garrick, Am J Sports Med, 1977.

Basler Behandlungs-Protokoll OSG-Distorsion

Grade	Symptoms	Ligament lesions	Therapy	
I°	Swelling, full-weight-bearing possible	Partial rupture lateral	Taping, bracing, 6 weeks of protection	
II°	Hematoma lateral, standing/walking only short distance	Total rupture lateral	Bracing for 6 weeks, full-weight-bearing according to pain	
III°	Hematoma lateral & medial, no full-weight-bearing due to pain	Total rupture lateral & involvement medial	Stable boot for 6-8 weeks, partial weight-bearing	
IV°	Joint dislocation, OCL, syndesmotic instability	All ligament lateral and medial as well as syndesmotic ligament ruptures	Surgery and functional rehabilitation with stable boot	

OSG-Distorsion – Konservative Behandlung

Kühlen, Hochlagern, Ruhen

Orthese:

- tape, brace, boot
- protection, ligament healing

Physiotherapie:

- lymphatic drains
- coordination, proprioception, strength
- collagen bridges [1]

Liu et al, Clin Orthop Relat Res, 1995.

OSG-Distorsion – Chirurgische Behandlung

Schwere Eversions-Verletzung

OSG-Distorsion – Chirurgische Behandlung

Schwere Eversionsverletzung

OSG-Distorsion – Chirurgische Behandlung

Schwere Eversionsverletzung

OSG-Distorsion – Chirurgische Behandlung

Schwere Eversionsverletzung

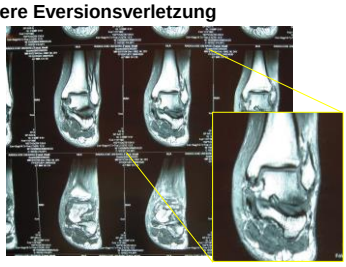

OSG-Distorsion – Chirurgische Behandlung

Schwere Eversionsverletzung

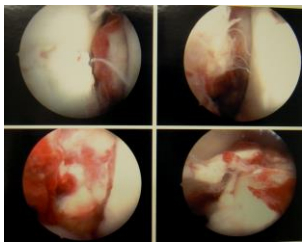

OSG-Distorsion – Chirurgische Behandlung

Schwere Eversionsverletzung

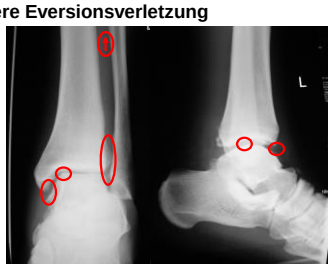

OSG-Distorsion – Chirurgische Behandlung

Schwere Eversionsverletzung

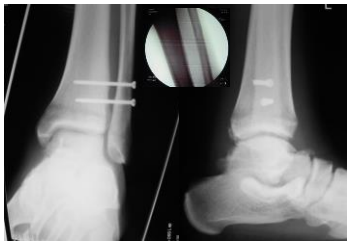

OSG-Distorsion – Chirurgische Behandlung

Schwere Eversions-Verletzung

Schraubenentfernung nach 8 Wochen

Intensive Physiotherapie/rehabilitation

Wettkampf-Niveau nach 5 Monaten

Chronische OSG-Instabilität

Leterale und mediale Instabilität

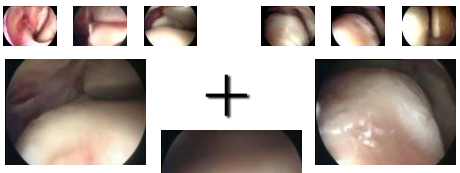

Lateral instability

Medial Instability

41j, f
recurrent sprains
first sprain 22 y ago

Chronische OSG-Instabilität

Laterale Bandrekonstruktion

Direct reconstruction, mod. Brostroem-Gould

Chronische OSG-Instabilität

Laterale Bandrekonstruktion

Direct reconstruction, mod. Brostroem-Gould

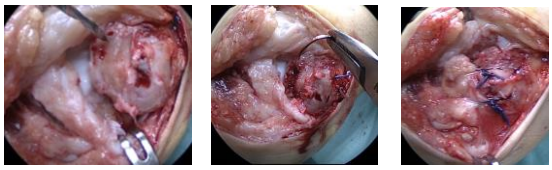

Chronische OSG-Instabilität

Laterale & Mediale Mediale Bandrekonstruktion

Lateral **Medial**

Nachbehandlung

Woche 1
Splint

Woche 2-6

Repair: stabilizing boot

Repair & Osteotomy:
partial weight-bearing boot

Woche 6-12

Physiotherapy

OSG-Instabilität und Arthrose

OSG-Instabilität und OCL / Arthrose

Stable Ankle

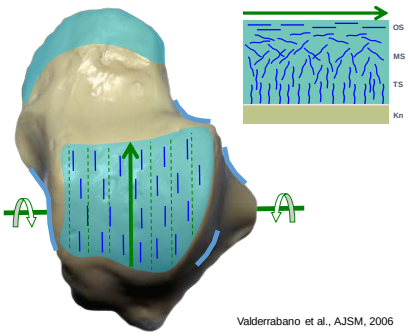

Valderrabano et al., AJSM, 2006

OSG-Instabilität und OCL / Arthrose

Unstable Ankle

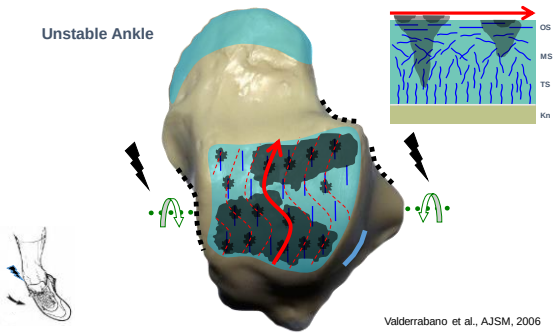

Valderrabano et al., AJSM, 2006

Oberes Sprunggelenk

Osteochondrale Läsion

Osteochondrale Läsion - Fall

36y, female

Sports active

Severe ankle pain

Pes planovalgus et abductus

Rotational CAI

Osteochondrale Läsion - Fall

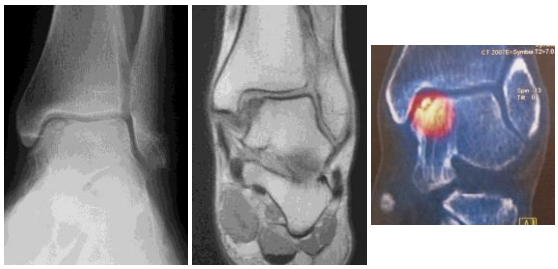

Osteochondrale Läsion - Fall

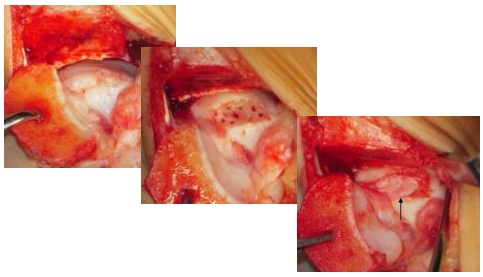

AMIC

Osteochondrale Läsion - Fall

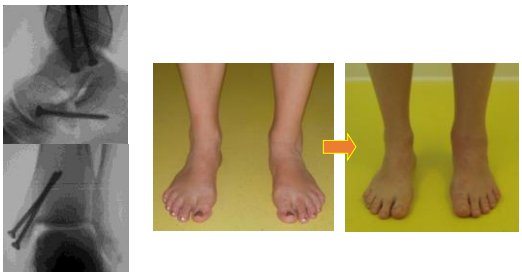

OCL - Hardware Removal & Debridement

23y, male, soccer player;

6 months postop

AMIC & Professional Soccer Player

27y, male, soccer player; 5 months postop

Oberes Sprunggelenk

Arthrose

Chirurgische Behandlung OSG-Arthrose

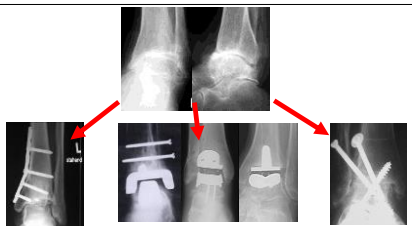

Gelenks-erhaltende Chirurgie | OSG-Prothese | OSG-Versteifung

Chirurgische Behandlung OSG-Arthrose

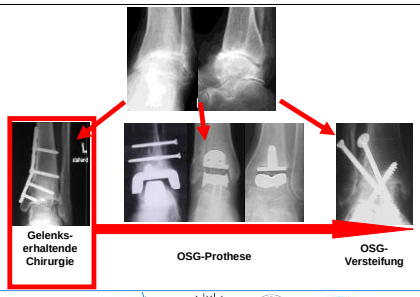

Gelenks-erhaltende Chirurgie | OSG-Prothese | OSG-Versteifung

Valgus Ankle OA & Pes Planovalgus Abductus

Case 1:

♂, 43 y.o., bus driver, moderate sport activities

Valgus Ankle OA & Pes Planovalgus Abductus

Case 1:

♂, 43 y.o., bus driver, moderate sport activities

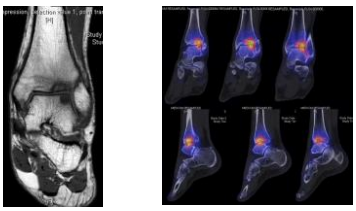

Valgus Ankle OA & Pes Planovalgus Abductus

Case 2:

♂, 43 y.o., bus driver, moderate sport activities

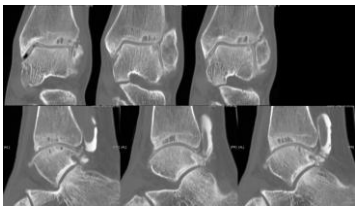

Valgus Ankle OA & Pes Planovalgus Abductus

Case 2:

Joint Preserving Surgery: med. closing wedge SMOT

Valgus Ankle OA & Pes Planovalgus Abductus

Case 2:

Joint Preserving Surgery: SMOT & Calcaneal length. OT

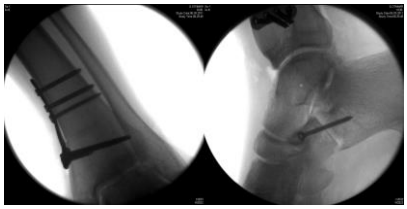

Valgus Ankle OA & Pes Planovalgus Abductus

1-year Follow-up

painfree, full ability to work

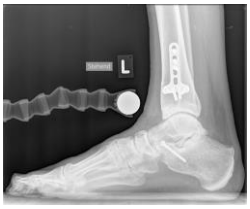

Chirurgische Behandlung OSG-Arthrose

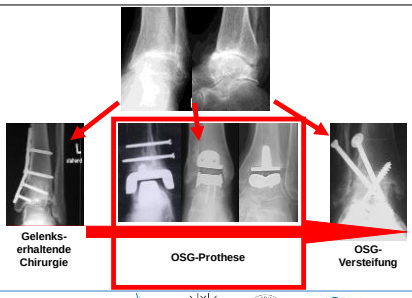

Sprunggelenksersatz / OSG-Prothese

Ideal-Fall OSG-Prothese

Posttraumatic Osteoarthritis
female, 69 y
tibial fracture 32 y ago
    conservative treatment
high disability
preoperative status
    well aligned
    stable
    DF / PF 15 – 0 – 30°
good bone stock

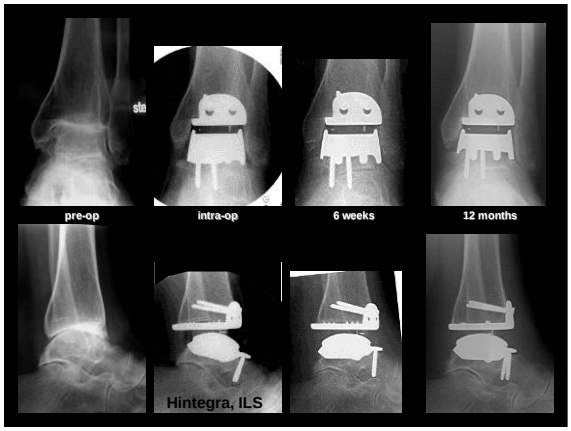

Häufig: OSG-Arthrose Achsenfehlstellung

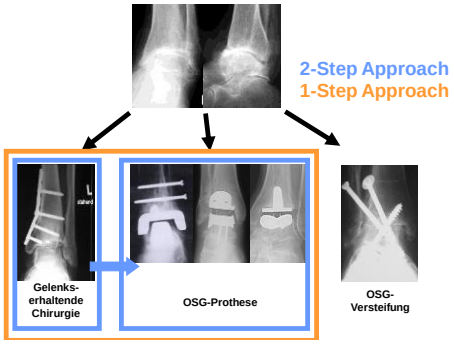

Sprunggelenksprothese

Rheumatoide Arthritis – Sprunggelenk & Rückfuss
♂, 82j, starke Schmerzen, nicht mobil

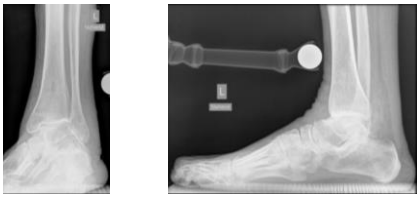

Sprunggelenksprothese

Operation: Sprunggelenksprothese, Rückfussversteifung

Letzte Kontrolle: 3 Jahre postoperativ: schmerzfrei, gute Mobilität

Posttraumatische OSG-Arthrose

72y, m
Very active

Posttraumatische OSG-Arthrose

Posttraumatische OSG-Arthrose

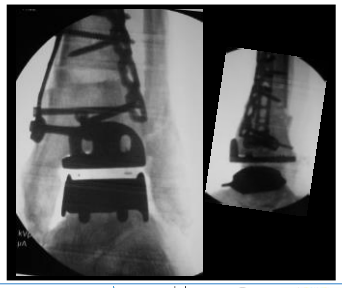

Supramalleolar Osteotomy & Total Ankle Replacement

Lower Leg Fracture

46y, male, France

Lower Leg Fracture

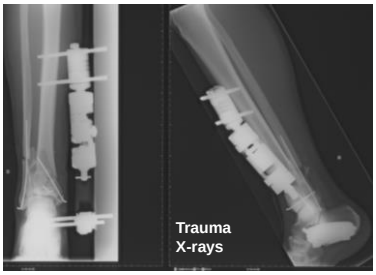

46y, male, France

Valgus Malaligned Ankle OA

46y, male, France, posttraumatic valgus ankle OA

Valgus Ankle OA & Knee Deformity

46y, male, France, posttraumatic valgus an

Valgus Ankle OA & Knee Deformity

Valgus Ankle OA & Knee Deformity

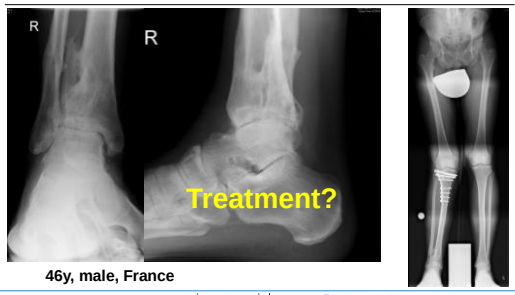

46y, male, France

Valgus Ankle OA & Knee Deformity

High Tibial Osteotomy

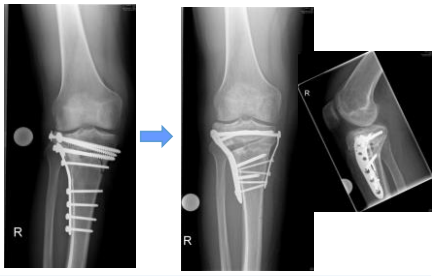

Valgus Ankle OA & Knee Deformity

High Tibial Osteotomy

&

TAR with Fibula OT

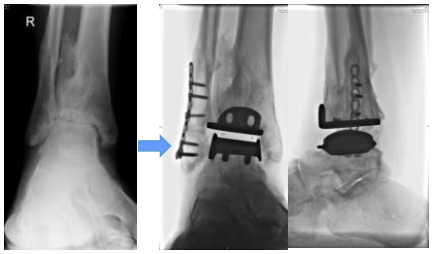

Valgus Ankle OA & Knee Deformity

High Tibial Osteotomy

&

TAR with Fibula OT

Valgus Malaligned Ankle OA – February 2015

66y, male, obese (195cm/ 135Kg)

Tri-malleolar ankle fracture with syndesmotic injury and Maisonneuve fracture in November 2014

4 surgeries:
1. Ex Fix
2. ORIF
3. Re-ORIF (February 2015)
4. Hardware removal and arthroscopy

Valgus Malaligned Ankle OA – June 2015

Valgus Malaligned Ankle OA – September 2015

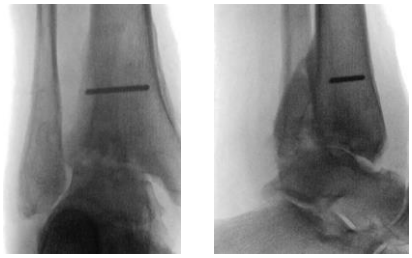

Valgus Malaligned Ankle OA – September 2015

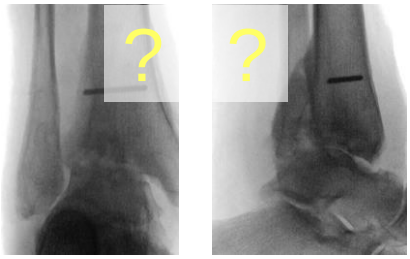

Valgus Malaligned Ankle OA – September 2015

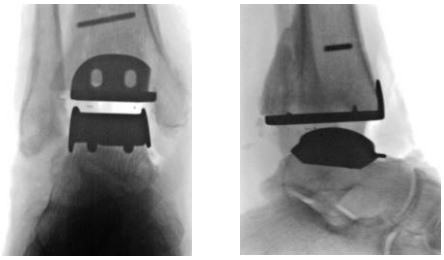

Valgus Malaligned Ankle OA – September 2015

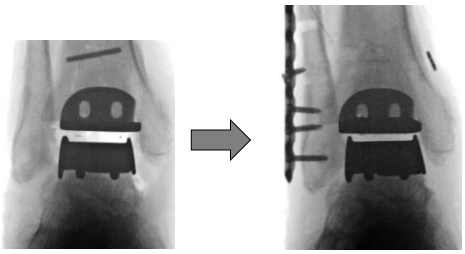

Valgus Malaligned Ankle OA – September 2015

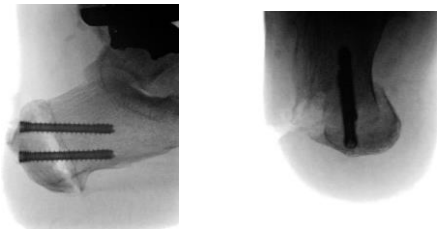

Chirurgische Behandlung OSG-Arthrose

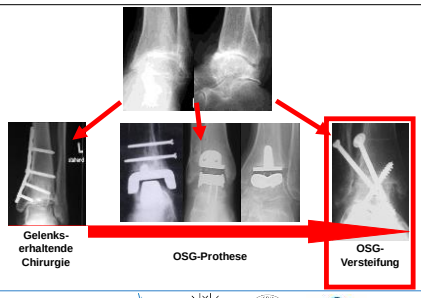

OSG-Versteifung

OSG-Versteifung

OSG-Versteifung bei Diabetischem Fuss

56y, male
Ankle / Hindfoot Charcot foot

OSG-Versteifung bei Diabetischem Fuss

56y, male
Ankle / Hindfoot Charcot foot
TM Ankle Spacer with HAN retrograde nail

Zimmer

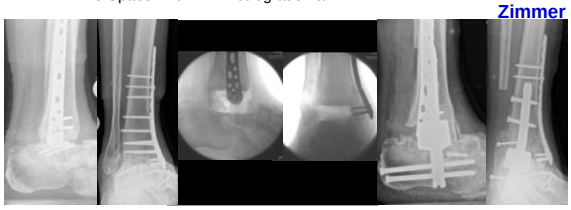

Rückfuss

Knicksenkfuss / Plattfuss

Tibialis posterior - Insuffizienz

Mediale Instabilität

Deformität planus
valgus
abductus

Schmerz medial
lateral

Progressiv

Endet in fixe Arthrose

des Rückfusses

Tibialis posterior - Insuffizienz

Mediale Instabilität

Deformität planus
valgus
abductus

Schmerz medial
lateral

Progressiv

Endet in fixe Arthrose

des Rückfusses

Konservative Behandlung

Grad I/II

Physical activity ↓ (4-6w)

Sports ↓

Physiotherapy

Insoles

Orthopaedic Shoe (orthosis)

→ Progressive entity!

Tibilias posterior-Insuffizienz - Fall

57j, f (L.M.)

Medial pain (VAS 6)

Progressive flafoot left

Reduced life quality

Clinical Signs of Grade II:

flexible Pes planovalgus

et abductus

Tibilias posterior-Insuffizienz - Fall

Medial Situs

PT: - Degeneration

- Longitudinal splitt

Tibilias posterior-Insuffizienz - Fall

Medial Situs

PT: - Degeneration

- Longitudinal splitt

Tear Spring-Ligament

Deltoid insufficiency

Tibilias posterior-Insuffizienz - Fall

Intraop. Strategy

1. Prepare medial
2. Lat. Calc. Leng. OT
3. Reconstruction medial

Suture Spring-Ligament Repair Deltoid

PT: Distal shortening to Navicular, FDL-PTT-Side to side-Augmentation

Tibilias posterior-Insuffizienz - Fall

Patient satisfied
No pain
Plantigrade hindfoot
IV-Force >75% of contral.

Mittelfuss

Plattfuss

Platffuss des Erwachsenen

♂, 24j, konservativ ausbehandelt
Pes planovalgus et abductus deformity (PPTD II°)

Platffuss des Erwachsenen

Double Calcaneus OT (CCS 7.0, 3.5 screw), Midfoot plate

Platffuss des Erwachsenen

Double Calcaneus OT (CCS 7.0, 3.5 screw), Midfoot plate

Platffuss des Erwachsenen

♂, 24 y.o., follow-up
Double Calcaneus OT (CCS 7.0, 3.5 screw), Midfoot plate

Vorfuss

Hallux

Hallux valgus

73 jährige Dame

Vorfussbeschwerden
Störung Hallux
Rückfussbeschwerden

Hallux valgus

73 jährige Dame

Vorfussbeschwerden
Störung Hallux
Rückfussbeschwerden

Hallux valgus

64 jährige Dame

Starke Vorfuss-Schmerzen
Einlagen nicht geholfen

Hallux valgus

Lapidus-Arthrodese
Akin-Osteotomie

Lisfranc-Arthrodese 2-3

Beidseits

Hallux valgus

Schwere Vorfuss-Deformität

75jährige Dame

Kann nicht mehr laufen
Vorfussschmerzen
Mehrfach operiert

Schwere Vorfuss-Deformität

75jährige Dame

Kann nicht mehr laufen
Vorfussschmerzen
Mehrfach operiert

Grosszehegelenksersatz / Hallux-Prothese

Hallux-Arthrose

♂, 63 y.o., hallux rigidus

Hallux-Arthrose

1 year follow-up

Zusammenfassung

Fuss-Deformitäten vielfältig

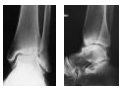

Konservative Behandlung wichtig

Moderne Fusschirurgie

Rekonstruktionen: Ziel:

Verbesserung der Biomechanik

Schmerzreduktion

Vielen Dank!

Prof. Dr. med. Dr. phil. Victor Valderrabano
Orthopädie-Traumatologie, Schmerzklinik Basel, Hirschgässlein 11-15, 4010 Basel
vvalderrabano@gsmn.ch